

Evaluation of healing effects of *Punica granatum* peel on acetic acid induced colitisArpit Verma¹, Nikita Toshi², Sandeep Kumar³, Shreyasi Vaksh⁴, Mukesh Pandey⁵

¹Senior Resident, Department of Pharmacology, AIIMS, Raipur, Chhattisgarh-492001, ²Junior Resident, Department of Dentistry, RIMS, Raipur, ³Junior Resident, Department of Community Medicine, IMS, BHU, Varanasi, ^{4,5}Associate Professor, Department of Physiology, RIMS, Raipur

Corresponding Address:

Email: arvhal@gmail.com

Abstract

The main objective is to evaluate the healing effects of 50% ethanolic extract of dried peel of *Punica granatum* (PGE) on acetic acid-induced colitis in rats. The method is *Punica granatum* peel extract was administered orally, once daily for 14 days in rats after the induction of colitis with 50% acetic acid and 100mg/ kg dose of extract was found to have optimal effect against acetic-acid-induced colonic tissue damage and adhesions. Effectiveness of above dose of extract was then further studied for its effects on fecal output, presence of blood/mucous, changes in body weight, food and water intake done till 14th day of experiment while colonic tissue damage score, colonic weight and adhesions in the colonic tissue were studied on 15th day of experiment in 18 hours fasting rats. Antibacterial activity of the extract was also studied using in vitro procedures. In results *Punica granatum* peel extract (PGE) decreased colonic mucosal damage and inflammation, faecal output and increased body weight. Acute toxicity study indicated no mortality or other ANS or CNS related adverse effects even with 1000 mg/ kg dose (10 times of effective dose) indicating its safety. The conclusion in this study is *Punica granatum* peel extract (PGE) seemed to be safe and effective in colitis decreasing intestinal bacteria responsible for tissue damage and delayed healing.

Abbreviations Used: PGE-*Punica granatum* peel extract; AA-Acetic Acid
CMC-Carboxy Methyl Cellulose; NS-Normal Saline
SS-Sulfasalazine; UC-Ulcerative Colitis

Keywords: *Punica granatum*, colitis

Introduction

Ulcerative colitis is a refractory, chronic, and nonspecific disease of colon. It typically involves the innermost lining (mucosa), manifesting as continuous areas of inflammation and ulceration. Symptoms include a progressive loosening of the stool, abdominal cramps, rectal bleed and loss of appetite that result in nutrient deficiencies, weight loss and anemia.⁽¹⁾ Although the exact cause of ulcerative colitis remains undetermined, the condition appears to be related to a combination of genetic, microbial and environmental factors that influence the normal intestinal commensal flora to trigger an inappropriate mucosal immune response. Among the pathological findings associated with UC are an increase in certain inflammatory mediators, signs of oxidative stress, a deranged colonic milieu, abnormal glycosaminoglycan content of the mucosa, decreased oxidation of short chain fatty acids and increased intestinal permeability.^(2,3) Reactive oxygen species (ROS) mediated injury plays an important role in the patho-physiology of UC. Chronic inflammation, infection or immune imbalance increases production of ROS and impairs antioxidant defenses, resulting in intestinal oxidative injury in UC patients.⁽⁴⁾

Punica granatum is an attractive shrub or small tree growing 6 to 10 m high with multiple spiny branches. The edible fruit is a berry and is 5–12 cm in diameter with a rounded shape and thick reddish skin (peel). In the Indian subcontinent's ancient Ayurveda system of medicine, the pomegranate has extensively been used as a source of traditional remedies being considered as a pharmacy in itself. It is used as an antiparasitic agent, hemostatic, antibacterial, anti-fungal, antiviral and as

remedy for cut wound, a blood tonic, an eyedrop and to heal ulcers. The peel of the fruit is used to treat diarrhea, dysentery and intestinal parasites. The astringent qualities of the flower juice, peel and tree bark are considered valuable for a variety of purposes, such as toning skin, firming-up sagging breasts, and treating hemorrhoids. Pomegranate has been used as a contraceptive and abortifacient by means of consuming the seeds and using the peel as a vaginal suppository. In south anatolia, turkey, some people employ the ashes of the fruit peel as protective against skin infection. *Plant* extract has been shown to possess Antinflammatory activity, Anticancer activity,⁽⁵⁾ anti-spermatogenic effect. It is highly valued for its neuroprotective property in stress-induced neuro-degeneration like Alzheimer's disease.⁽⁵⁾ It has anti-atherogenic effect & demonstrates hypoglycemic activity in diabetic rats.

The present study was undertaken to evaluate healing effects of 50% ethanol extract of *Punica granatum* peel extract (PGE) in acetic acid-induced colitis in rats.

Materials and Methods

Animals- Inbred Charles: Foster albino rats (160-180 g) and mice (25-30 g) of either sex were obtained from the central animal house of Institute of Medical Sciences, Banaras Hindu University, Varanasi. They were kept in the departmental animal house at 26 ± 20 C and relative humidity 44-56%, light and dark cycles of 10 and 14 h respectively for 1 week before and during the experiments. Animals were provided with standard rodent pellet diet (Pashu Aahar, Ramnagar, and Varanasi) and water ad libitum. 'Principles of laboratory

animal care' (NIH Publication No. 82-23, revised 1985) guidelines were followed. Approval from the Institutional Animal Ethical Committee was taken prior to the experimental work (Notification no.: Dean/12-13/CAEC/10 dated 11.01.2013).

Plant material and preparation of extract: Whole plant of *Punica granatum* was collected in the months of September–November from Ayurvedic Gardens, Banaras Hindu University. The peel were dried in shade and blended to form fine powder and used. 50% ethanolic extract of PG (PGE) was prepared by adding 200 g of dried fine powder of PG peel in 1000 ml of ethanol (500 ml) and distilled water (500 ml) mixture. The mixture was shaken at intervals and the extract so obtained was filtered after an interval of two days. The procedure was repeated twice at an interval of two days. PGE so obtained each time was mixed and later dried at 40°C in incubator. The yield was about 20% (w/w). PGE was stored at -20°C until further use. Enough quantity of the extract was prepared fresh before use.

Drug and chemicals: Sulfasalazine (SAZO, WALLACE); acetic acid obtained from Merck Ltd., Mumbai, India, and all the other chemicals and reagents were used of analytical grade.

Induction of colitis and treatment protocol: Experimental colitis was produced by intra colonic administration of acetic acid (10%, 0.20 ml/100 g rat) given per rectally.⁽⁶⁾ A dose response study was first undertaken with 50% ethanol extract of *Punica granatum* peel (PGE) (50,100 and 200 mg/kg) when given orally for a period of 14 days after the induction of UC with acetic acid and on 15th day of experiment, the healing effect was studied on the colonic mucosal damage score, weight and adhesions in acetic acid-induced colitis. 100 mg/kg of *Punica granatum* peel extract showed optimal protective effects against acetic acid-induced changes on the colonic mucosal weight, damage score and adhesions and was used for further detailed study on faecal output, food intake and water intake and body weight changes on the day 0, 4, 7, 10 and 14 of experiment in acetic acid-induced colitis rats. The animals were sacrificed on 15th day after intra-colonic administration of either normal saline (negative control) or acetic acid (control) and after treatments with *Punica granatum* peel extract (test extract, 100 mg/kg) and sulfasalazine (positive control, 100 mg/kg)⁽⁸⁾ in acetic acid induced colitis rats. PGE and standard UC protective drug, sulfasalazine suspension was prepared in 0.5% carboxy-methyl cellulose (CMC) and administered orally, once daily in the volume of 1ml/100 g rat for 14 days after the induction of colitis. The results of the acetic acid group were compared with normal saline group while the treatment groups were compared with acetic acid group.

Assessment of faecal output and changes in body weight, food and water intake: Faecal output and changes in body weight, food and water intake were observed in intra colonic normal saline and intra colonic

acetic acid-induced colitis per se and after administration of PGE and sulfasalazine. 24 hr faecal output of individual rat was measured and then faecal output was calculated for each group. Similarly, each rat of normal saline/acetic acid and acetic acid plus PGE/ sulfasalazine group was individually weighed using standard rat weighing machine and their respective weights were noted down. Weight/volume of food/water was measured after giving fixed amount of food and water in the respective cage to each rat at a fixed time of day and next day the amount of food and water left was measured again to calculate the amount of food and water intake by an individual rat. The above effects were seen on day 0 (before induction) and after 4, 7, 10 and 14th day of induction of colitis. The result of acetic acid was compared with normal saline (without colitis) while that of PGE/sulfasalazine treated groups were compared with acetic acid group on respective day study.

Assessment of colonic damage and inflammation: All scorings of damage and excision of tissue samples were performed by an observer unaware of the treatment group. The rats in the various treatment groups were randomized before being sacrificed. The rats were weighed and sacrificed by over dose of ether and proximal 8 cm of colon was removed. The colon was opened by a longitudinal incision, rinsed with tap water and pinned out on a wax block. Macroscopically visible damage was scored on a 0-10 scale using the scoring system as described by Morris et al.,⁽⁶⁾ which takes into consideration the area of involvement and the presence or absence of ulcers, adhesions to surrounding tissue and thickness. Subsequently 8 cm of colon were taken for measurement of weight and the weight was then expressed as mg/per cm length of colon.

Antimicrobial susceptibility and minimum inhibitory concentration: *In vitro* antibacterial susceptibility test of PGE was done using serial concentrations of 50, 100, 150 and 200 mg/ml following the approved standards of the National Committee for Clinical Laboratory Standards⁽⁷⁾ against various intestinal pathogens i.e. *Escherichia coli* ATCC 25922, *Shigella boydii*, *Shigella sonnei* and *Shigella flexneri* obtained from the American Type Culture Collection (ATCC) and clinical strain preserved at Department of Microbiology, Institute of Medical Sciences, BHU, Varanasi, India following the disk diffusion method while, minimum inhibitory concentration (MIC) was performed by micro dilution method.⁽⁸⁾

Acute toxicity study in mice: Adult Charles Foster strain albino mice of either sex, weighing between 20 to 25g fasted overnight, were used for toxicity study. Suspension of PGE was orally administered at 1000 mg/kg stat dose (10 times of the optimal effective dose of 100 mg/kg) to mice. Subsequent to PGE administration, animals were observed closely for first four hours, for any toxicity manifestation, like increased motor activity, salivation, convulsion, coma and death. Subsequently observations were made at regular

intervals for 24 h. The animals were under further investigation up to a period of 14 days.⁽⁹⁾

Statistical analysis: This comparison was performed using either unpaired 't' test or ANOVA and for multiple comparisons versus control group was done by Dennett's test. All statistical analysis was performed using SPSS statistical version 16.0 software package (SPSS® Inc., USA). P value <0.05 were considered statistically significant.

Results

Effects on body weight, food and water intake: AA-induced colitis led to gradual decrease in body weight as

observed from day 4 onwards till 14th day of study (9.6 to 21.4%, P<0.05 to P<0.001) compared with respective day control. Treatment with 100 mg/kg dose of PGE for 14 days reversed the decrease trend in body weight compared with AA control group of respective Day, suggestive of beneficial effects of the test extract (6.7 to 20.3%, P<0.1 to P<0.01). The results of the above extract on body weight showed a similar effect as shown by sulfasalazine-treated rats (6.8 to 24.4%, P<0.1 to P<0.001) (Fig. 7). However, little or no change was observed on food and water intake between the AA-treated and PGE and SS treated animals from 0 day to 14th day of study treatments (Table 1).

Table 1: Effects of PGE and SS treatment on Body Weight in AA-induced colitis in rats

Oral treatment (mg/kg, Once daily x 14 days)	Day 0	Day 4	Day 7	Day 14
NS + CMC 1%	166.6 ± 4.42 (100.0 ± 2.65)	175.9 ± 4.12 (105.6 ± 2.47)	188.3 ± 4.79 (113.0 ± 2.88)	204.2 ± 3.28 (122.6 ± 1.96)
AA + CMC 1%	169.7 ± 5.29 (100.0 ± 3.11)	163.2 ± 3.29* (96.2 ± 1.91)	161.8 ± 4.43** (95.3 ± 2.61)	171.7 ± 5.21*** (101.2 ± 3.07)
AA + PGE 100	162.5 ± 5.9 (100.0 ± 3.63)	167.5 ± 4.13 (103.1 ± 2.54)	177.5 ± 5.13 ^a (109.2 ± 3.16)	197.5 ± 3.97 ^b (121.5 ± 2.44)
AA + SS 100	165.8 ± 4.74 (100.0 ± 2.85)	170.8 ± 4.74 (103.0 ± 2.86)	188.3 ± 3.17 ^c (114.2 ± 1.91)	208.3 ± 6.17 ^b (125.6 ± 3.72)

Results are mean ± SEM of 6 rats in each group.

P values: *<0.05, **<0.01 and ***<0.001 compared to respective Day NS group (unpaired 't' test) and ^a<0.05, ^b<0.01, compared to respective day AA group (Statistical analysis was done by one way analysis of variance followed by Dunnett's test for multiple comparisons).

Effects on fecal output and presence of blood or mucus: 10% AA when instilled intra-rectally into the colon led to severe diarrhea in all the animals (100%) which was prominent on day 2 and then decreased to 50% of animals on day 4 and was associated with presence of blood till 7th day and mucous till day 10.

Table 2: Effects of PGE and SS treatment on Stool Frequency in AA-induced colitis in rats

Oral treatment (mg/kg, Once daily x 14 days)	Day 0	Day 4	Day 7	Day 14
NS + CMC 1.0%	3.82 ± 0.11 100.0 ± 2.88	4.09 ± 0.10 107.0 ± 2.62	4.07 ± 0.12 106.5 ± 3.14	4.11 ± 0.21 107.6 ± 5.51
AA + CMC 1.0%	3.71 ± 0.22 100.0 ± 5.93	6.70 ± 0.21* 180.6 ± 5.66	6.38 ± 0.17* 172.0 ± 4.58	5.67 ± 0.19* 152.8 ± 5.12
AA + PGE 100	3.66 ± 0.32 (100.0 ± 8.74)	5.48 ± 0.26 ^b (149.7 ± 7.10)	4.37 ± 0.33 ^c (119.4 ± 9.01)	4.23 ± 0.24 ^c (115.6 ± 6.56)
AA + SS 100	4.01 ± 0.21 (100.0 ± 5.24)	5.04 ± 0.3 ^b (125.7 ± 6.48)	4.67 ± 0.23 ^c (116.5 ± 5.73)	4.21 ± 0.16 ^c (105.0 ± 3.99)

Results are mean ± SEM of 6 rats in each group.

P values: **<0.01, ***<0.001 compared to respective Day NS group (unpaired 't' test) and ^b<0.01, ^c<0.001, compared to respective day AA group (Statistical analysis was done by one way analysis of variance followed by Dennett's test for multiple comparisons).

Treatment with PGE led to decrease in blood/mucous in the stool. AA intra-colonic treated rats showed an increase in stool frequency from day 4 onwards (80.6%)

and the intensity of stool frequency was maintained over day 7 (72.0% increase, P<0.001) onwards to day 14 (52.8% increase, P<0.001 compared with Day 0 frequency. Administration of PGE (100 mg/kg) in AA treated rats showed decrease in stool frequency from day 4 onwards from 30.9 to 37.2% (P<0.01 to P<0.001) and was comparable with sulfasalazine (47.8 to 54.9.0%, P<0.01 to P<0.001) compared with AA control (Table 2).

Effects on colonic damage, inflammation and adhesions:

Untreated rats (a negative control group), were given normal saline (NS) instead of AA in the colon intrarectally and 1% CMC orally daily through an orogastric tube. They did not show any colonic mucosal damage or adhesions at 15th day of experiment while, the colonic weight (8 cm of proximal colon) expressed as mg/cm of colon was found to be 134.4 ± 7.22 mg/cm. The AA group received 1% CMC orally daily as above but was given AA in the colon intrarectally in the dose mentioned above. AA treatment led to significant increase in colonic mucosal damage score (5.0 ± 0.36 , $P < 0.001$) and adhesions (5/6 rats, 83.3%) and increase in colonic weight to 208.0 ± 11.4 (33.3% increase) compared with NS group indicating an extensive colonic tissue damage, inflammation together with adhesions. PGE was given in graded doses of 50,100,200 mg/kg for 14 days, once daily, orally as suspension in 1% CMC showed dose-dependent decrease in damage score from 17.0% to 56.8% ($P < 0.05$ to $P < 0.001$), colonic weight from 12 to 22.8% ($P < 0.01$ to $P < 0.05$) and tissue adhesions from (40.0 to 60.0 %). From the above dose response study, PGE (100 mg/kg) showing good healing effects on colonic mucosal damage score and inflammation were selected for future studies. Further their effects were comparable with sulfasalazine, a known drug for treatment of ulcerative colitis (a positive control) (Fig. 1-3).

Acetic Acid- Induced Colonic Mucosal Study

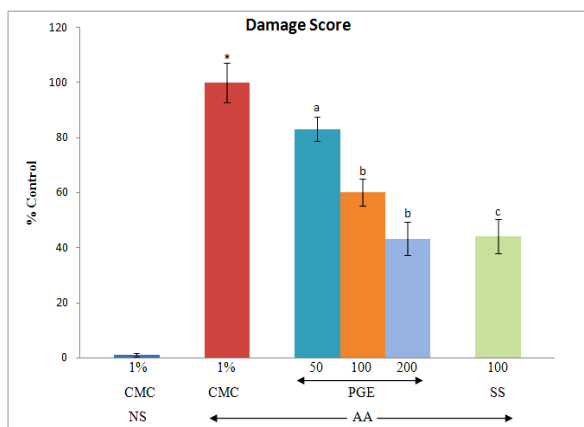


Fig. 1: Effect of graded doses of PGE & SS on AA-induced colonic mucosal damage score in rat

Results are mean \pm SEM of 6 rats in each group.

P values: * < 0.001 compared to NS group (unpaired 't' test) and ^b < 0.01 , ^c < 0.001 , compared to respective AA group (Statistical analysis was done by one way analysis of variance followed by Dunnett's test for multiple comparisons).

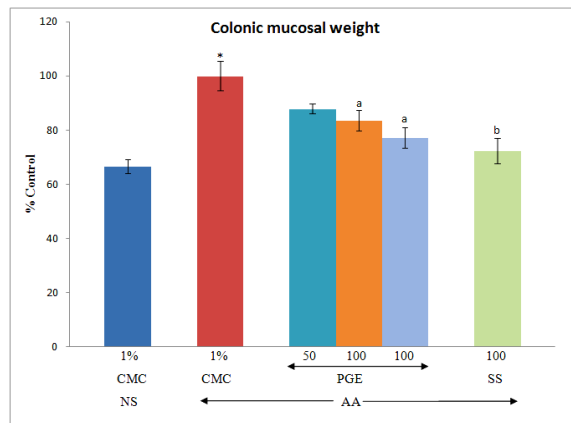


Fig. 2: Effect of graded doses of PGE and SS on AA-induced rat colonic mucosal weight

Results are mean \pm SEM of 6 rats in each group. P values: * < 0.001 compared to NS group (unpaired 't' test) and ^a < 0.05 , ^b < 0.01 , compared to respective AA group (Statistical analysis was done by one way analysis of variance followed by Dunnett's test for multiple comparisons).

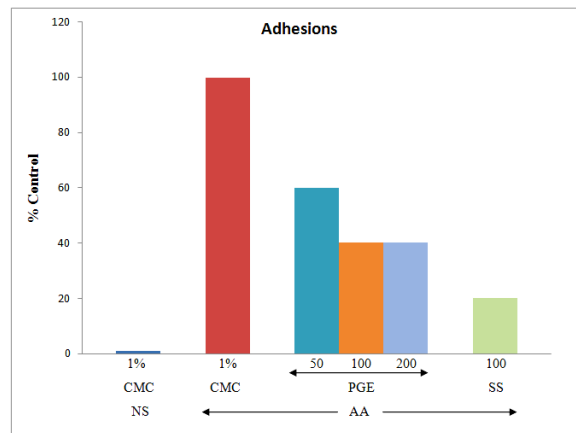


Fig. 3: Effect of graded doses of PGE and SS on AA-induced rat percent adhesion

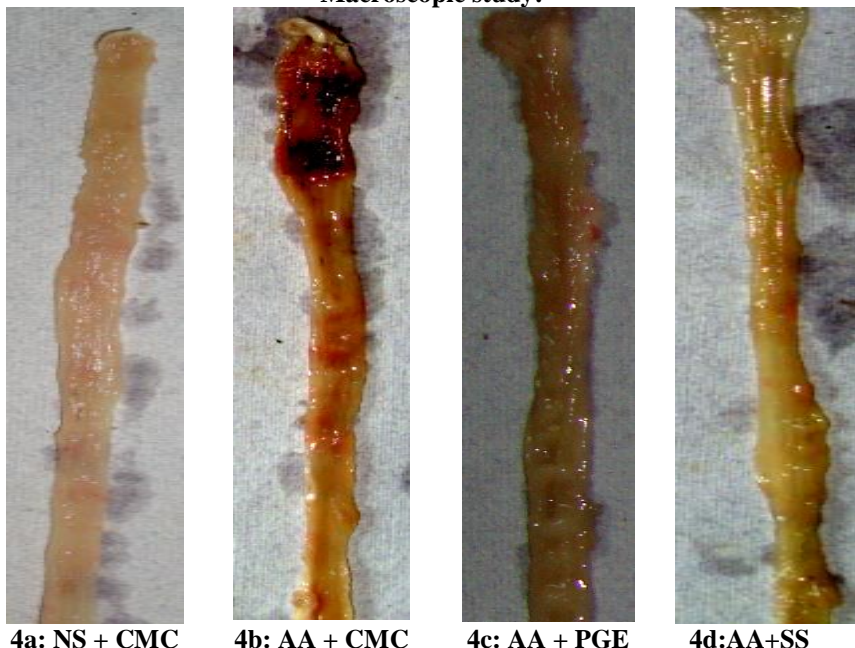
Macroscopic study:**Fig. 4: AA-Induced Colitis Macroscopic Study****Macroscopic study:**

Fig. 4a: Macroscopic changes seen in saline enema treated colon of CMC-treated rat showing normal morphology.

Fig. 4b: Macroscopic changes seen in the colon of AA-induced colitis rat treated with CMC showing hydropsia, necrosis, erosion and ulceration.

Fig. 4c: Macroscopic changes seen in the colon of AA-induced colitis rat treated with PGE (100 mg/kg) showing reduction in ulceration, erosion, necrosis and hydropsia.

Fig. 4d: Macroscopic changes seen in the colon of AA-induced colitis rat treated with SS (100 mg/kg) showing reduction in ulceration, erosion, necrosis and hydropsia.

Acute Toxicity Study: The result of the acute toxicity study with different doses of 10 times of the optimal effective dose of 50% ethanolic extract of PG did not show any change in ANS, CNS or mortality in mice till 14 days of study indicating them to be safe.

Discussion

Acetic acid-induced colitis has been reported to resemble human inflammatory bowel disease in terms of the prolonged colonic inflammation and serves as a useful model to investigate the role of free radicals and antioxidants in the pathophysiology of colitis.⁽¹⁰⁾ Our results with intracolonic administration of acetic acid showed increase in faecal output and loss of body weight without any significant change in the food and water intake. Diarrhoea with loss in body weight could be due to alterations in the GIT absorptive functions. Acetic acid intracolonic administration also led to significant increase in colonic mucosal damage score and adhesions (indicative of necrosis and ulcerations) and increase in

colonic weight (indicative of inflammation and oedema) probably due to the direct necrotic action and subsequent inflammation and bacterial invasions. Rats treated with PGE showed significant decrease in colonic weight, necrosis and ulceration (decrease in colonic damage score and adhesions) enhanced in acetic acid induced colitis and showed regenerative mucosa and its effect was comparable with sulfasalazine-treated group. These above effects may be attributed to the anti-inflammatory, anti-nociceptive and antiulcer properties of PGE. The presence of anti-inflammatory activity in PGE may be attributed to other pharmacologically active constituents such as ellagic acid, ellagitannins, punicalic acid flavonoids, anthocyanidins, anthocyanins, and estrogenic flavonols and flavones isolated earlier.^(11,12) Flavonoids are most commonly known for their antioxidant activity. Thus, PGE could have potential role in the therapy of various inflammatory conditions including UC.

Conclusions

The results of the present study revealed that 50% ethanolic extracts of *Punica granatum* peel have significant healing activity in both AA-induced colitis rats as observed by decrease in colonic mucosal damage score, adhesions and weight (confirmed by macroscopic study of colon) and decrease in diarrhoea, fecal output, presence of fecal mucous/blood and increase in body weight suggestive of beneficial effects of treatment. Further, PGE seemed to be safe and did not produce any lethal effect.

Conflict of interest statement: We declare that we have no conflict of interest.

Acknowledgments: The authors' express sincere thanks to Department of Pharmacology, Faculty of Medicine, Institute of Medical Sciences, Banaras Hindu University, Varanasi, India, for providing the best facilities and funding for the research work.

References

1. Kathleen A, Jurenka JS. Inflammatory Bowel Disease Part I: Ulcerative colitis pathophysiology and conventional and alternative treatment options. *Alt Med Review* 2003;8(3):247–283.
2. Benson JM, Shepherd DM. Aryl hydrocarbon receptor activation by TCDD reduces inflammation associated with Crohn's disease. *Toxicol Sci* 2010;120(1):68–78.
3. Molodecky NA, Kaplan GG. Environmental risk factors for inflammatory bowel disease. *Gastroenterol Hepatol* 2010; 6(5): 339–346.
4. Khor B, Gardet A, Xavier RJ. Genetics and pathogenesis of inflammatory bowel disease. *Nature* 2011;474(7351):307–317.
5. Akhlaghi M, Band B. Mechanisms of flavonoid protection against myocardial ischemia reperfusion injury. *J Mol Cell Cardiol* 2009;46:309-17.
6. Gautam MK, Goel S, Ghatule RR, Singh A, Nath G, Goel RK. Curative effect of Terminalia chebula extract on acetic acid-induced experimental colitis: role of antioxidants, free radicals and acute inflammatory marker. *Inflammopharmacol* 2012.
7. National Committee for Clinical Laboratory Standards NCCLS. Methods for dilution antimicrobial susceptibility tests for bacteria that grow aerobically: approved standards fifth edition. NCCLS document M7-A5, (Wayne, PA, USA.) NCCLS, 2000.
8. Wiegand I, Hilpert K, Hancock REW. Agar and broth dilution methods to determine the minimal inhibitory concentration (MIC) of antimicrobial substances. *Nature Protocols* 2008; 3: 163–175.
9. Gautam MK, Singh A, Rao CV, Goel RK. Toxicological evaluation of *Murraya paniculata* (L.) leaves extract on rodents. *Am J Pharm Toxicol* 2012;7(2):62–67.
10. Tahan G, Aytac E, Aytekin H, Gunduz F, Dogusoy G, Aydin S, et al. Vitamin E has a dual effect of anti-inflammatory and ulcerative colitis in rats. *Can J Surg* 2011; 54 (5): 333–338. antioxidant activities in acetic acid-induced ulcerative colitis in rats. *Can J Surg* 2011;54(5):333–338.
11. Lansky EP, Newman RA. *Punica granatum* and its potential for prevention and treatment of inflammation and cancer. *J Ethnopharmacol* 2007;109:177-206.
12. Pirbalouti AG, Koohpayeh A, Karimi I. The wound healing activity of flower extracts of *Punica granatum* and *Achillea kellalensis* in Wistar rats. *Acta polonia pharmaceutics drug research* 2010;67(1):107-110.