

Apexification with apical plug of MTA- report of cases

Abhishek Shukla^{1,*}, Ruchika Dewan², Pragya Kumar³, Sonali Taneja⁴¹Assistant Professor, ²Professor, ³Associate Professor, ⁴Professor & Head, Dept. of Conservative Dentistry & Endodontics, ITS Centre for Dental Studies & Research, Ghaziabad***Corresponding Author:**

Email: drabhishekshuklamds@gmail.com

Abstract**Back ground:** Immature teeth with necrotic pulp and large periapical lesion are difficult to treat via conventional endodontic therapy. The role of materials such as calcium hydroxide and Mineral trioxide aggregate (MTA) are indispensable. These case reports present successful healing and apexification using MTA.**Methods:** The case reports present two cases with traumatized upper anterior teeth. The radiographic evaluation revealed open apices with blunderbuss canals; the canal was cleaned using intracanal instruments and 5.25% NaOCl and final irrigation with 2% chlorohexidine. To obtain canal disinfection slurry of calcium hydroxide was temporized in the canal. In subsequent appointments 3-4mm apical stop was created with mineral trioxide aggregate and allowed to set. Subsequently the root canals were obturated with thermoplasticized guttapercha. A composite resin restoration sealed the access cavity. A 3 month, 6 month and 1 year follow-up revealed clinically asymptomatic and adequately functional tooth.**Results:** A positive clinical resolution of this case is encouraging for the use of white MTA as a apical plug, in immature teeth with open apex.**Conclusion:** Apexification in one step using an apical plug of MTA can be considered a predictable treatment and may be an alternative to use a long term calcium hydroxide apexification.**Keyword:** Apical plug; MTA; Apexification

Access this article online	
Quick Response Code:	Website: www.innovativepublication.com
	DOI: 10.5958/2394-2738.2016.00030.3

Introduction

Complete aseptis and three dimensional obturation of the root canal system are essential for long term endodontic success. In certain cases such as immature teeth, absence of natural apical constriction creates a challenge. Therefore one of the aims of endodontic treatment is to form an apical barrier or a stop against which one can place root canal filling material avoiding over extrusion. This technique is termed as apexification.¹

Clinicians have tried several materials to form apical barrier in the past. These include, calcium hydroxide powder, calcium hydroxide mixed with different vehicles, collagen calcium phosphate, osteogenic protein, bone growth factor and oxidized cellulose. Deliberate over instrumentation to produce blood clot that will induce apical closure has also been described.²

Mineral trioxide aggregate (MTA) was developed at Loma Linda University as root end filling material. Using MTA apexification can be carried out in single visit which is advantageous over traditional calcium

hydroxide apexification which requires treatment time of 5–20 months to induce the formation of a calcific barrier.³

Apexification using MTA has several advantages as it neither gets resorbed nor weakens the root canal dentin and also sets in wet environment. Satisfactory compaction of filling material can be achieved as MTA forms hard and non-resorbable apical barrier.⁴ Torabinejad et al. (1995), Xavier et al. (2005) suggested that mineral trioxide aggregate is most biocompatible and bacteriostatic material with good sealing property, which stimulates cell growth, adhesion and proliferation.⁵

Therefore the present case reports highlight the non surgical management of asymptomatic tooth with blunderbuss canal using MTA apical plug technique.

Case Reports

Case 1: A 18 year old male patient, reported to the Department of Conservative Dentistry & Endodontics, Vananchal Dental College, Gharwa (Jharkhand) with a chief complaint of discoloured right maxillary central incisor with the history of trauma at the age of 9. The concerned tooth did not respond to both electric and heat test. Detailed radiographic examination revealed a large blunderbuss canal with associated periapical lesion in relation to maxillary right central incisor (**Fig. 1**).

There are two treatment options either surgical removal of periapical lesion and retrograde filling or non surgical root canal treatment followed apexification using apical plug of MTA. Considering the amount of

surgical trauma and the age of the patient non-surgical treatment was opted. Access opening was prepared under rubber dam isolation and working length was determined (**Fig. 2**).

Pus was extruded from the root canal immediately after access preparation; luke warm water was used to irrigate the root canal and was left open till exudate stopped draining out of the canal. Biomechanical preparation was done using no 80 K-file using circumferential filing motion. Root canal debridement was done using alternate irrigation with 2.5% NaOCl and saline. Calcium hydroxide and iodoform combination was placed in the root canal and patient recalled after one week. At subsequent appointment after removal of dressing root canal was found completely dry and canal was debrided with 2.5% NaOCl followed by 17% EDTA and final rinse with 2% chlorohexidine. The canal was dried with paper points and Mineral trioxide aggregate was placed with MTA carrier in the apical portion of the canal, subsequent increments were condensed with hand pluggers till thickness of 2-5mm (**Fig. 3**).

A wet cotton pellet was placed, access cavity sealed with temporary cement. In subsequent appointment root canal was back filled with Obtura II access cavity sealed with composite (**Fig. 4**).

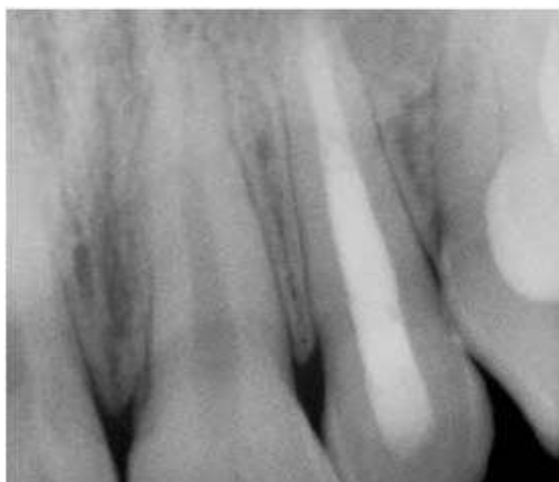

Fig. 1

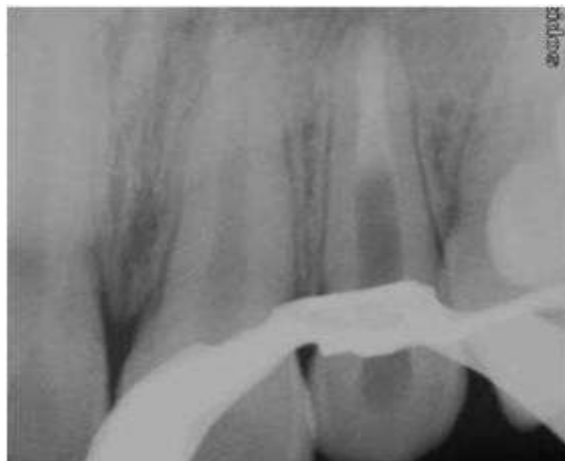

Fig. 2

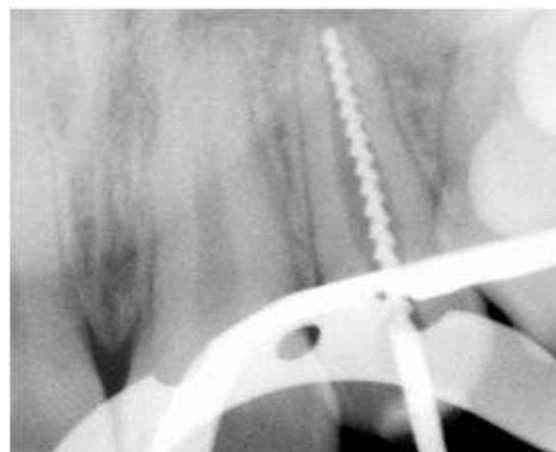


Fig. 3

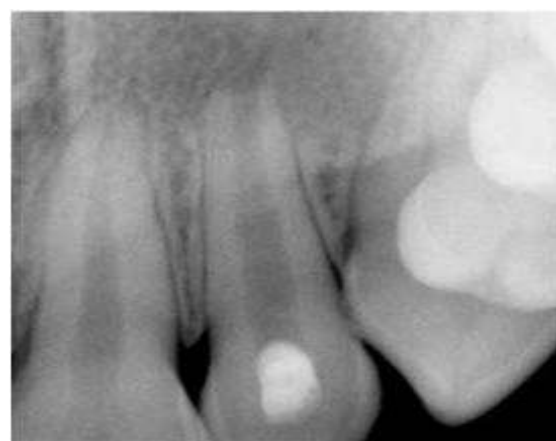

Fig. 4

Case 2: A 26 years male patient, reported with chief complaint of pus discharge in upper front region since 2 months. Clinical examination revealed discolored and fractured maxillary right lateral incisor with Grade I mobility (**Fig. 5**).

Tooth showed no response to vitality tests. Radiographic examination revealed a large blunderbuss canal with an open apex. Access was prepared under

rubber dam isolation followed by working length determination (**Fig. 6**). Biomechanical preparation was using #70 K-file and root canal was irrigated alternately with 2.5% NaOCl and saline. Root canal was dried and Calcium hydroxide dressing (Calcium hydroxide + saline) was placed for 1 week. In subsequent appointment root canal was dry, the canal was derided using 2.5% NaOCl and 17% EDTA. The canal was

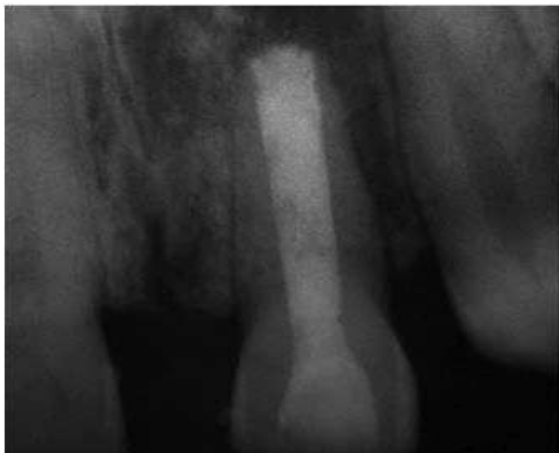

Fig. 5

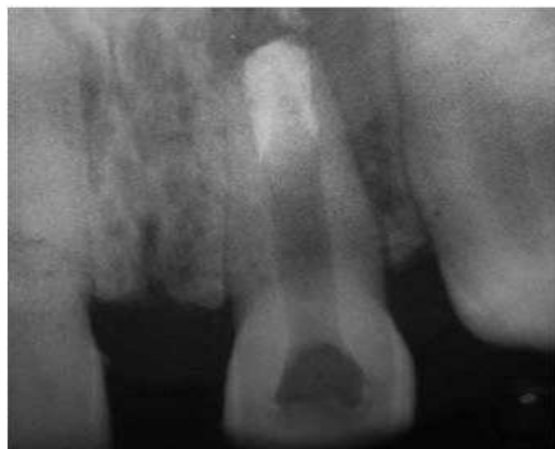

Fig. 6

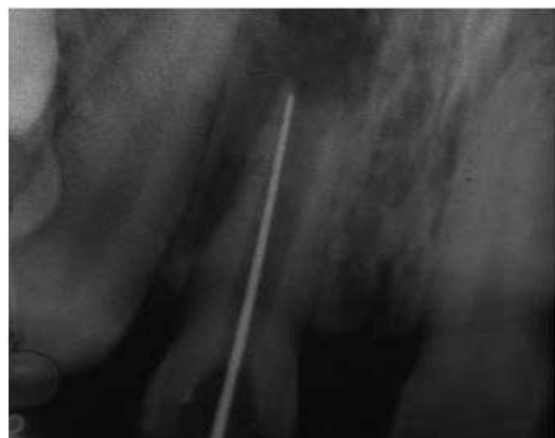

Fig. 7

dried with paper points and MTA was condensed using MTA condenser in apical region till the thickness of 3-5 mm (**Fig. 7**), a moist cotton pellet was placed inside the access cavity sealed with temporary cement. In subsequent appointment root canal was back filled with Obtura II and access cavity sealed with composite (**Fig. 8**).

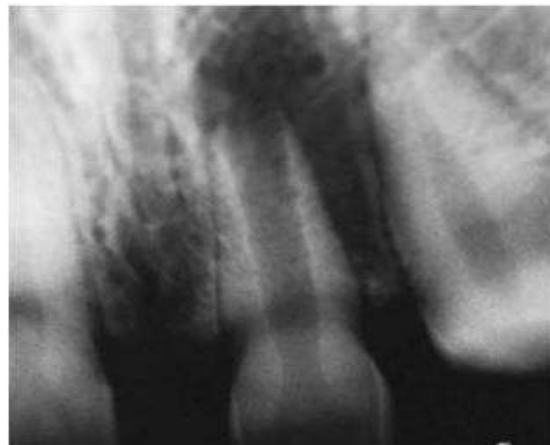

Fig. 8

Discussion

Apexification treatment is supposed to create an environment to permit deposition of cementum, bone and periodontal ligament to continue its function of root development. The goal of this treatment is to obtain an apical barrier to prevent the passage of toxins and bacteria into periapical tissues from root canal. Technically this barrier is necessary to allow compaction of root filling material.^{3,4}

Despite higher success rate of apical barrier formation using calcium hydroxide long term follow-up is essential. Previous studies have described the disadvantages of calcium hydroxide apexification such as failure to control infection, recurrence of infection and cervical fracture.⁶

Mineral trioxide aggregate as an apexification material represents a primary monoblock. Appetite like interfacial deposits form during the maturation of MTA result in filling the gap induced during material shrinkage phase and improves the frictional resistance of MTA to root canal walls. The formation of nonbonding and gap filling appetite crystals also accounts for seal of MTA.⁷

MTA has superior bio-compatibility and it is less cytotoxic due to its alkaline pH and presence of calcium and phosphate ions in its formulation results in capacity to attract blastic cells and promote favorable environment for cementum deposition.^{8,9} 5 mm barrier is significantly stronger and shows less leakage than 2 mm barrier.¹⁰

The novel approach of apexification using MTA lessens the patient's treatment time between first

appointment and final restoration. Importance of this approach lies in thorough cleaning of root canal followed by apical seal with material that favors regeneration. In addition there is less chance of root fracture in immature teeth with thin roots because the material immediately bonds with the roots and strengthens it.

Conclusion

Single visit apexification with a novel biocompatible material like MTA is a new boon in effective management of teeth with open apex. This innovative procedure is predictable and less time consuming one.

References

1. Felipe WT, Felipe MC, Rocha MJ. The effect of mineral trioxide aggregate on the apexification and periapical healing of teeth with incomplete root formation. *Int Endod J.* 2006;39(1):2-9.
2. Coomaraswamy KS, Lumley PJ, Hofmann MP. Effect of bismuth oxide radio-opacifier content on the material properties of an endodontic Portland cement-based (MTA-like) system. *J Endod.* 2007;33:295-298.
3. Komabayashi T, Spångberg LS. Comparative analysis of the particle size and shape of commercially available mineral trioxide aggregates and Portland cement. *J Endod.* 2008;34:94-97.
4. Martin Trope. Treatment of immature teeth with non vital pulps and apical periodontitis. *Endotopic.* 2007;14:51-59.
5. Kogan P, He J, Glickman GN, Watanabe I. Effects of various additives on setting properties of MTA. *J Endod.* 2006;32:569-572.
6. Maroto M, Barbería E, Planells P, Vera V. Treatment of a non-vital immature incisor with mineral trioxide aggregate (MTA). *Dent Traumatol.* 2003;19(3):165-169.
7. Torabinejad M, Chivian N. Clinical implications of mineral trioxide aggregate. *J Endod.* 1999;25:197-205.
8. Weldon JK Jr, Pashley DH, Loushine RJ, Weller RN, Kimbrough WF. Sealing ability of mineral trioxide aggregate and super-EBA when used as furcation repair materials: a longitudinal study. *J Endod.* 2002;28:467-470.
9. De-Deus G, Petrucci V, Gurgel-Filho E, Coutinho-Filho T. MTA versus Portland cement as repair material for furcal perforations: a laboratory study using a polymicrobial leakage model. *Int Endod J.* 2006;39:293-298.
10. Matt GD, Thorpe JR, Strother JM, McClanahan SB. Comparative study of white and gray mineral trioxide aggregate (MTA) simulating a one- or two-step apical barrier technique. *J Endod.* 2004;30:876-879.