

Muscular branches of posterior femoral cutaneous nerve

Shavi Garg^{1,*}, Sushil Kumar Srivastava², Vishal Singla³, Ashish Singla⁴

¹Assistant Professor, ²Professor & Head, Dept. of Anatomy, SGT Medical College, Hospital & Research Institute, Gurgaon, ³Senior Resident, Dept. of Anaesthesia, SHKM, GMC Nuh, ⁴Medical Officer, GH Mewat

*Corresponding Author:

Email: shavigarg6@gmail.com, vishalksingla@yahoo.com

Access this article online	
Quick Response Code:	Website: www.innovativepublication.com
	DOI: 10.5958/2394-2738.2016.00011.X

Introduction

The posterior femoral cutaneous nerve is one of the branches from the sacral plexus formed by ventral rami of L4 to S4 spinal nerves.

The textbooks of Anatomy describe the posterior femoral cutaneous nerve as a sensory nerve, the skin over the lower part of the gluteal region, the perineum, the posterior surface of the thigh and the posterior surface of the leg. The posterior femoral cutaneous nerve derives its fibres from the posterior divisions of the ventral rami of the first and second and anterior divisions of the ventral rami of second and third sacral nerves.

Bardeen and Elting & Hortwitz² have described prefixed and postfixed types of lumbosacral plexus on the basis of spinal nerves taking part in the formation of this plexus. Thane has described the formation of this plexus.³ Thane has described the formation of the posterior femoral cutaneous nerve by two divisions in the gluteal region particularly when the two divisions of the i.e. tibial and common peroneal of the sciatic nerve were separate at their origin.³ Hollinshed has described the variations in the segmental origin of the posterior femoral cutaneous nerve, which may derive its fibres from the fourth lumbar to the fourth sacral nerve.⁴ No muscular branch arising from the posterior femoral cutaneous nerve or any of its branches has been reported in the available literature.

During the routine dissection of the lower limbs, the muscular branches arising from the posterior femoral cutaneous nerve and supplying the gluteus maximus muscle was noticed. In order to determine whether this occurrence was a rare anomaly or it was a common variation, the present study was undertaken.

Materials and Methods

The material used for present study consisted of 80 lower limbs (40 cadavers), which were observed during routine dissection in the Anatomy department of Pt.

B.D. Sharma PGIMS, Rohtak. The gluteal region was dissected carefully and the formation, course and branches of the posterior femoral cutaneous nerve were studied. A specific observation was made for any muscular branch arising from the posterior femoral cutaneous nerve or any of its branches and supplying the gluteus maximus muscle.

Observations and Results

Among the 80 lower limbs studied in two limbs (2.5%), the posterior femoral cutaneous nerve was found to be present in the form of two roots. These roots were joining to form a single trunk in the lower part of the thigh (Fig. 1). The perineal branch of the posterior femoral nerve was arising separately by two roots from the roots of the posterior femoral cutaneous nerve in these limbs. From this perineal branch, there was one muscular branch supplying the gluteus maximus muscle (Fig. 1) in these two limbs. In the remaining limbs, the nerve was present in the form of a single trunk. The Ischial Tuberosity is surrounded by these critical nerves.⁵

In 8 out of 80 limbs (10.0%), it was observed that the muscular branches from the perineal branch of the posterior femoral cutaneous nerve were present and supplying the gluteus maximus muscle (Fig. 1-4). In 2 left lower limbs (2.5%), it was noticed that a communicating branch from the posterior femoral cutaneous nerve was joining the inferior gluteal nerve (Fig. 5) and through that it was supplying the gluteus maximus muscle.

In 6 limbs (7.5%) there was a single muscular branch from the perineal branch of the posterior femoral cutaneous, which divided into two branches before entering the gluteus maximus muscle (Fig. 2 & 3). In 2 limbs (2.5%) there were two muscular branches arising from the perineal branch of the posterior femoral cutaneous nerve (Fig. 4).

The muscular branch in the form of a communicating branch from the posterior femoral cutaneous nerve to the inferior gluteal nerve was present in the form of a single trunk in 2 limbs (2.5%) (Fig. 5).

The left posterior femoral cutaneous nerve supplied the gluteus maximus through its perineal branch in 4 bodies (10.0%) and through a communicating branch to the inferior gluteal nerve in 2 bodies (5.0%), while the right posterior femoral cutaneous nerve supplied the

gluteus maximus muscle through its perineal branch in 4 bodies (10.0%). There was no incidence of bilateral supply to the gluteus maximus muscle.

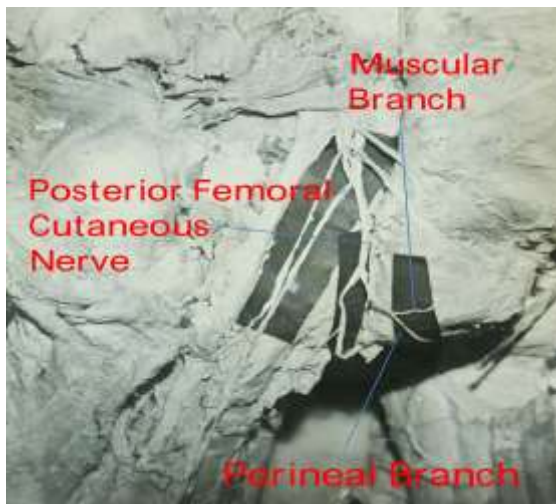


Fig. 1



Fig. 2



Fig. 3

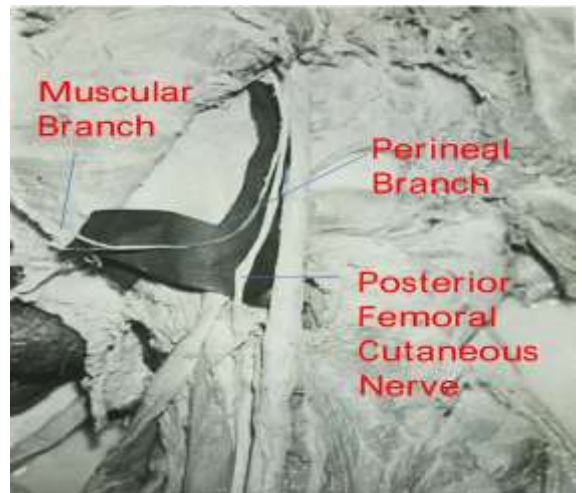


Fig. 4



Fig. 5

Discussion

Thane has described the formation of the posterior femoral cutaneous nerve by two divisions.³ Similar pattern was found in 2 limbs (2.5%).

The posterior femoral cutaneous nerve is considered to be supplying to the skin only and there is no reported case of supply to the gluteus maximus muscle from this nerve or any of its branches in the available literature.

As seen in the present study, in 10 limbs (12.5%) the posterior femoral cutaneous nerve was supplying the muscular branches to the gluteus maximus muscle either through its perineal branch or through a communication with the inferior gluteal nerve. Out of these 10 cases in two limbs (2.5%) there was a communicating branch from the posterior femoral cutaneous nerve to the inferior gluteal nerve; in the remaining 8 limbs (10.0%) the perineal branch of the posterior femoral cutaneous nerve was supplying muscular branches to the gluteus maximus muscle either as a single branch or as two branches.

The possible explanation for the origin of these muscular branches from the posterior femoral cutaneous nerve or one of its branches to the gluteus maximus muscle, could be an anomalous route of some of the fibres of the inferior gluteal nerve, because the fibres of the dorsal or posterior divisions of the ventral rami of first and second sacral nerves are present in both these nerves.

Summary and Conclusions

From the present study following conclusions are drawn:

1. In 12.5% limbs, the posterior femoral cutaneous nerve or its perineal branch were giving rise to muscular branches to the gluteus maximus muscle.
2. In 8 out of 80 limbs (10.0%), the perineal branch of the posterior femoral cutaneous nerve was supplying muscular branches to the gluteus maximus muscle.
3. In 6 limbs(7.5%),there was a single muscular branch and in 2 limbs (2.5%),there were two muscular branches from the perineal branch of the posterior femoral cutaneous nerve.
4. In 2 limbs (2.5%), a communicating branch from the posterior femoral cutaneous nerve was joining the inferior gluteal nerve and through that it was supplying the gluteus maximus muscle.
5. Out of 40 bodies dissected, the posterior femoral cutaneous nerve or its perineal branch were supplying muscular branches to the gluteus maximus muscle unilaterally in all 10 cases (25.0%) and there was no incidence of bilateral muscular supply.
6. In two limbs (2.5%), the posterior femoral cutaneous nerve was present in the form of a plexus having two roots. These roots joined to form a single trunk in the lower part of the back of thigh. In the same limb, the perineal branch was arising by two roots from the roots of the posterior femoral cutaneous nerve.

Entrapment of the perineal branch of posterior femoral cutaneous nerve (PBPFNC) may be the cause of some forms of the perineal pain syndrome. Specific knowledge of the (PBPFNC) may assist surgeons in releasing and anesthetizing this cutaneous nerve of the perineum.

References

1. Bardeen, CR. and Elting, AW. A statistical study of the variations in the formation and position of the lumbosacral plexus in man. *Anat Anz* 1901;19:124, 209.
2. Horwitz, MT. The anatomy of the lumbosacral nerve plexus – its relation to variations of vertebral segmentation. *Anat Rec* 1939;74:91.
3. Sharpey-Schäfer EA, George Dancer Thane Longmans GDT, Green. *Quain's Elements of Anatomy*.1895;3(2).
4. Hollinshed HW. *Anatomy for Surgeons. The back and limbs*. Philadelphia, 1958:614-5,823-31.

5. Pain with sitting related to injury of the posterior femoral cutaneous nerve. *Dellon AL Microsurgery*. 2015 Sep;35(6):463-8.
6. Tubbs RS, Miller J, Loukas M, Shoja MM, Shokouhi G, Cohen-Gadol AA. Surgical and anatomical landmarks for the perineal branch of the posterior femoral cutaneous nerve: implications in perineal pain syndromes. *Laboratory investigation. J Neurosurg*. 2009 Aug;111(2):332-5.